



16/6/2020

4115

Time: 5:25 PM

Dr. Noreen @ Ram Mrs Noorjahan age 40
w/o late Poshan B/O Ram garh
Range Rajaji park Achar road
Dehradun
S/O Noor Mahmad sister
Mg - fib in rt side ca.

- 1) In my Multiple abrasion on back of left shoulder
- 2) No pain on rt wrist
- 3) No pain, swelling on left lower leg
- 4) No pain on rt lower leg
- 5) No pain on lower back

Similar but above in my subject has
hant & but object of duration of
nature simple



R T I of Noorjahan



REDMINOTES PRO
MI DUAL CAMERA

HOSPITAL UPADHYAYA GOVT. COMBINED HOSPITAL, DEHRADUN
MEDICOLEGAL

Date: 17/06/2020 Time: 12:30 pm

Case No. E-621A
I/O: Agashi Kandon carefully examined.
Mrs. Namjahan 49 yr Female.
W/o - Late Ratan das (Divorced)
No - Ashrodi, Ramgarh Range Near Van
Vibhag Guest House Roorkee.
Mo - R.T.I.
Bo - Bapoor (Brother)

A/H/O - Assault

O/E - pt. is cons., oriented to time, place
person. GC - fair.

Vitals - BP - 110/70 mmHg
P - 80/min
SpO2 - 98%

Injury - (1) Laceration of 0.5 cm over scalp
active bleeding.

H/O - LOC +ve.

- No NCT head
(1) Neuro ref.

Opinion - Above injury is fresh in duration,
may be caused by hard/blunt obj.
Ntox can only be established
radiological inv. 4 ortho. ref.

2020/6/18 16:55

RIFI
attested
Kandon
i.e.

JEENDAYAL UPADHYAYA GOVT. COMBINED HOSPITAL, DEHRADUN
MEDICOLEGAL

EOPD No. 031 E-6217, Date: 17/06/2020 Time: 12:20 PM

IDr. Ayushi Kandon carefully examined

Mr. Ramzan Bibi 49/F

W/o- Noor Mohammad

Mo- Asharadi, Dehradun

Moi- R.T.I.

Bia- Baseer (Brother-in-law)

a/h/o Assault

of E-pts is cons., oriental to time, place +
person. G.C. fair

Vitals - BP- 110/80 mmHg

PR- 82/min

SpO2 - 98%

Injury @ Multiple scratch marks over (R)
forearm.

(ii) Swelling + Tenderness (L) forearm.

Adv @ X-ray forearm left AP
full length left.

(ii) Ortho. reference.

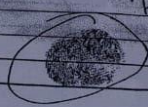
Opinion - Above injuries are fresh in duration,
may be caused by hard blunt object.

Nature can be told after rad. Po. inv +
ortho. opinion.

R.T.I.

attested

Kandon



Kandon